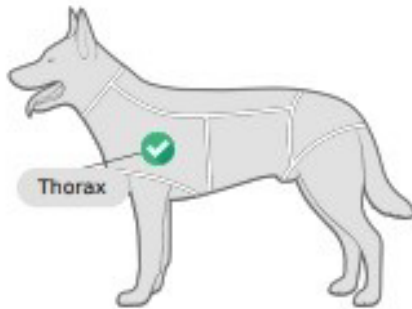


Virtual Radiologist CANINE Cardiopulmonary Evaluation by Vetology AI

Region: Thorax



CASE AI EVALUATION REPORT:

Case		Patient	
ID		ID:	
DOS	05/25/2022	Name:	
Priority	Normal	Current Age:	9 y. 7 m.
Clinic		Age when report:	9 y. 7 m.
		Sex:	M
		Species:	Canine
		Breed:	
		Weight:	0.00 kg
Email:			
Phone:			
Fax:			



Vetology Innovations
San Diego, CA.
vetology.ai

Artificial Intelligence (AI) Evaluation

Virtual Radiologist CANINE Cardiopulmonary Evaluation : Abnormal

Airway/Pulmonary Findings:

1) A minimal perihilar infiltrate has been detected. Clinical signs are necessary to ascribe significance to this radiographic finding. In the ABSENCE of respiratory signs, this appearance could be secondary to pulmonary hypoinflation +/- concurrent, fluid in the caudal thoracic esophagus, or non-clinical chronic interstitial lung disease. If left atrial enlargement is present, that could also result in this radiographic appearance (see cardiac findings below). In the PRESENCE of respiratory signs, minimal chronic interstitial lung disease and/or active pneumonitis (viral, heartworm disease, inhaled allergen, toxin or uremic) may be more likely.

2) There is no evidence of BRONCHITIS, ALVEOLAR PATTERN, DYNAMIC AIRWAY COLLAPSE or BRONCHIECTASIS, PULMONARY NODULES or PLEURAL EFFUSION.

Cardiac Findings:

1) The cardiac silhouette size is normal.

Seth Wallack, DVM, DACVR
Vetology Founder. Creator of Radiology AI Algorithms

Next Steps

NOTE: We expect the Vetology AI virtual radiologist to perform at the level of a boarded veterinary radiologist. If our virtual radiologist result is inconsistent with the clinical picture or you believe is incorrect, click: [I want a Vetology radiologist 2nd opinion.](#)

Best virtual radiologist results are obtained when the system detects **ORTHOGONAL THORACIC RADIOGRAPHS** that are well positioned, properly exposed, unobstructed and non-contrast. If you think our system did not identify an image or missed something, click [here](#) and tell us about it.

Your Notes:

Further evaluation/treatment of the lungs and/or airways may include

1. Radiograph submission to a Radiologist for further evaluation.
2. Empirical therapy for lung disease based on your clinical assessment.
3. Bronchoscopy with bronchoalveolar lavage (BAL) vs. endotracheal lavage and/or Baermann fecal.
4. Oxygen therapy. Monitor respiratory rate.
5. Cardiac ultrasound, ECG and systemic blood pressure evaluation when the pet is stable.
6. Continue furosemide.
7. IV, IM or SQ furosemide. IF POSSIBLE, obtain pre-treatment blood and urine samples.